

# Administration Case Report: Open Posterior Lumbar Fusion

This case report represents the individual experience of Dr Michael Y. Wang, and is intended to demonstrate his methodology for using EXPAREL in patients undergoing open posterior lumbar fusion.

Pacira BioSciences, Inc. recognizes that there are alternative methodologies for administering local anesthetics, as well as individual patient considerations when selecting the dose for a specific procedure.

EXPAREL is a local anesthetic that produces postsurgical analgesia in patients aged 6 years and older. It is administered via single-dose infiltration. When infiltrated into the surgical site, it produces local analgesia. It may also be infiltrated in the fascial plane to produce regional analgesia as a regional field block. Regional anesthetic techniques to produce regional analgesia include, but are not limited to, transversus abdominis plane (TAP) block, pectoralis (PEC) and serratus anterior plane (SAP) blocks, erector spinae plane (ESP) block, and quadratus lumborum (QL) block. EXPAREL may also be administered as an interscalene brachial plexus nerve block in adults to produce postsurgical regional analgesia in total shoulder arthroplasty (TSA) and rotator cuff repair (RCR) procedures.

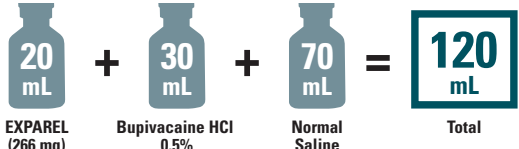
## CASE INFORMATION

Physician Name	Michael Y. Wang, MD, FACS
Affiliation	Director of Neurosurgery, Lois Pope LIFE Center Department of Neurosurgery, Miami, FL
Surgical Case Performed	Open posterior lumbar fusion
Inpatient or Outpatient Procedure	Inpatient

## PATIENT CHARACTERISTICS

Gender	Male
Age	67 years
Patient History and Characteristics	Patient had lumbar spinal stenosis, significant L2-L3 spondylosis, L4-L5 spondylolisthesis, and L5-S1 spondylosis. He presented with intractable back and leg pain for which he had failed conservative measures and elected to have surgical treatment

## PROCEDURAL DETAILS

Incision Size	10 cm
Preoperative Medications Used	None
Preoperative Analgesics Used	None
Intraoperative Analgesics Used	General anesthesia: propofol, remifentanyl, EXPAREL, bupivacaine HCl, and midazolam
Dose of EXPAREL and Total Volume Used	 <p>20 mL EXPAREL (266 mg) + 30 mL Bupivacaine HCl 0.5% + 70 mL Normal Saline = 120 mL Total</p>

The recommended dose of EXPAREL for adults is based on the size of the surgical site, the volume required to cover the area, and individual patient factors that may impact the safety of an amide local anesthetic. The maximum dose of EXPAREL should not exceed 266 mg. The recommended dose of EXPAREL for patients aged 6 to <17 years old is 4 mg/kg, up to a maximum of 266 mg. The maximum dose of EXPAREL for interscalene brachial plexus nerve block in adults should not exceed 133 mg.

EXPAREL can be administered unexpanded (20 mL) or expanded to increase volume up to a total of 300 mL (final concentration of 0.89 mg/mL [ie, 1:14 dilution by volume]) with normal (0.9%) saline or lactated Ringer's solution.

Bupivacaine HCl (which is approved for use in patients aged 12 and older) may be administered immediately before EXPAREL or admixed in the same syringe, as long as the ratio of the milligram dose of bupivacaine HCl to EXPAREL does not exceed 1:2. Admixing may impact the pharmacokinetic and/or physicochemical properties of EXPAREL, and this effect is concentration dependent. The toxic effects of these drugs are additive and their administration should be used with caution, including monitoring for neurologic and cardiovascular effects related to local anesthetic systemic toxicity. Other than with bupivacaine, EXPAREL should not be admixed with other drugs prior to administration.

**Please see Important Safety Information on the last page and refer to the accompanying full Prescribing Information, which is also available at [www.EXPAREL.com](http://www.EXPAREL.com).**

## INFILTRATION NOTES

### ASSESSED THE SIZE OF THE SURGICAL SITE AND DEPTH OF TISSUE, THEN PREPARED INJECTION MATERIALS ACCORDINGLY

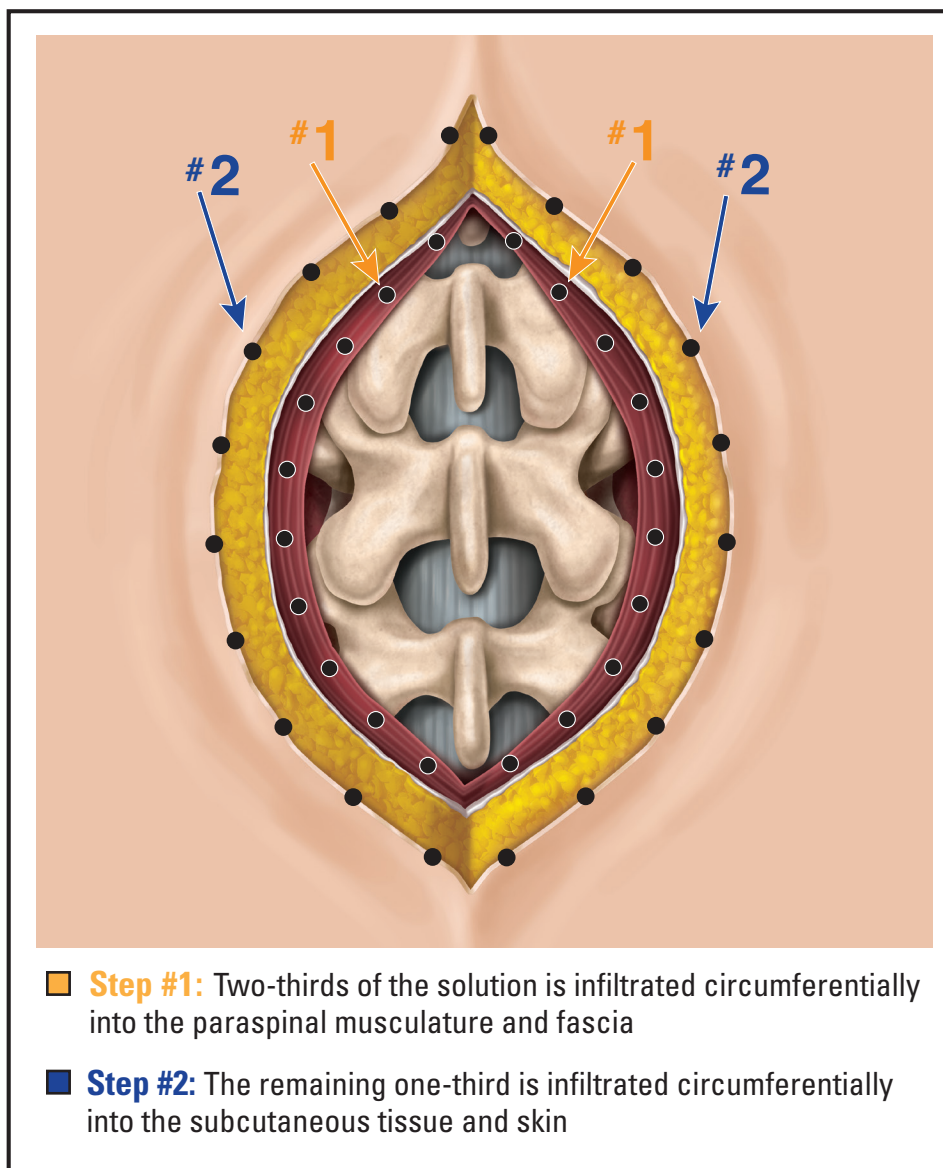
In this procedure, Dr Wang determined a total volume of approximately 120 mL would be needed to cover the surgical site. He expanded 20 mL of EXPAREL® (bupivacaine liposome injectable suspension) with 70 mL of normal saline and admixed this solution with 30 mL of 0.5% bupivacaine HCl. Bupivacaine HCl was admixed to provide short-term local analgesia in the postanesthesia care unit that overlapped with the long-term local analgesia provided by EXPAREL.



Use a thinner, small-gauge spinal needle, as it allows for closely spaced injections and deeper penetration with less trauma.

### DIVIDED INJECTATE INTO SYRINGES WITH NEEDLE SIZES APPROPRIATE FOR INFILTRATION (20- TO 25-GAUGE) AND PLANNED WHICH AREAS TO INFILTRATE WITH EACH INJECTION

For this procedure, Dr Wang used a 21-gauge spinal needle and divided the injectate into six 20-mL syringes and infiltrated as follows:



## INFILTRATION NOTES (cont)

### ■ Step #1:

Starting at the apex of the surgical site, Dr Wang infiltrated 3 to 5 mL of expanded EXPAREL® (bupivacaine liposome injectable suspension) every 1.0 to 1.5 cm circumferentially around the incision into the paraspinal musculature (total of 80 mL). For each injection, he inserted the needle at a 30-degree angle through the muscle and posterior layer of the thoracolumbar fascia into the deep paraspinal musculature ( $\approx$ 1 cm from bottom). Dr Wang injected as he withdrew the needle, ensuring expanded EXPAREL was also infiltrated into the more superficial paraspinal musculature (ie, above posterior layer of thoracolumbar fascia).

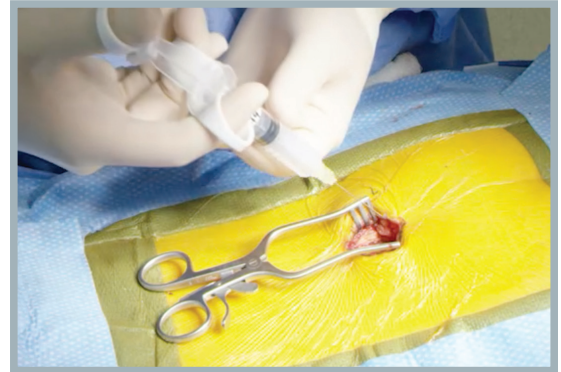

FIGURE 1. Paraspinal musculature



Watch the medial side of the fascial layer expand as the expanded EXPAREL is infiltrated. Be sure not to pierce through the bottom of the deep paraspinal musculature, as this can cause the expanded EXPAREL to leak out of the musculature and provide inconsistent analgesia.

### ■ Step #2:

Starting at the apex of the surgical site, Dr Wang infiltrated 1 to 2 mL of expanded EXPAREL every 1.0 to 1.5 cm circumferentially around the incision into the subcutaneous tissue and skin (total of 40 mL). For each injection, he inserted the needle horizontally into the dermal-subcutaneous junction. Dr Wang injected as he withdrew the needle, ensuring expanded EXPAREL was also infiltrated into the more medial subcutaneous tissue closer to the incision.

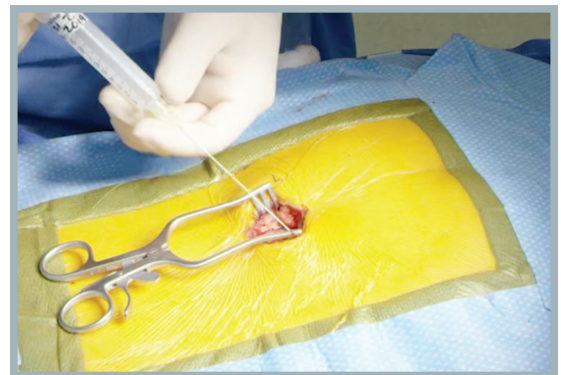


FIGURE 2. Subcutaneous tissue and skin

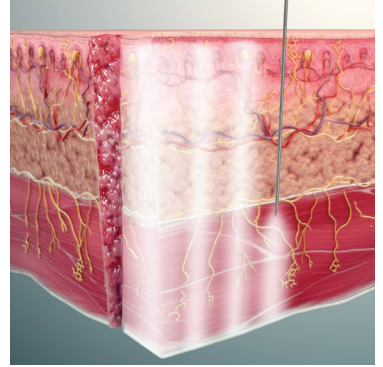


Tissue should visibly expand following infiltration, with minimal leakage.

## INFILTRATION NOTES (cont)

### PROPER TECHNIQUE IS CRUCIAL FOR ANALGESIC COVERAGE

Dr Wang infiltrated EXPAREL® (bupivacaine liposome injectable suspension) into all tissue layers using a moving needle technique. With a moving needle technique, the injections were spread in a fan-like pattern and occurred as the needle was withdrawn to maximize the coverage area. This technique was systematically and meticulously repeated at each injection site, with overlapping diffusion of EXPAREL to ensure there were no gaps in analgesic coverage.



Watch Dr Wang infiltrate with EXPAREL at [www.EXPAREL.com](http://www.EXPAREL.com)

### Important Safety Information

EXPAREL is contraindicated in obstetrical paracervical block anesthesia.

Adverse reactions reported in adults with an incidence greater than or equal to 10% following EXPAREL administration via infiltration were nausea, constipation, and vomiting; adverse reactions reported in adults with an incidence greater than or equal to 10% following EXPAREL administration via interscalene brachial plexus nerve block were nausea, pyrexia, and constipation.

Adverse reactions with an incidence greater than or equal to 10% following EXPAREL administration via infiltration in pediatric patients six to less than 17 years of age were nausea, vomiting, constipation, hypotension, anemia, muscle twitching, vision blurred, pruritus, and tachycardia.

If EXPAREL and other non-bupivacaine local anesthetics, including lidocaine, are administered at the same site, there may be an immediate release of bupivacaine from EXPAREL. Therefore, EXPAREL may be administered to the same site 20 minutes after injecting lidocaine.

EXPAREL is not recommended to be used in the following patient populations: patients <6 years old for infiltration, patients younger than 18 years old for interscalene brachial plexus nerve block, and/or pregnant patients.

Because amide-type local anesthetics, such as bupivacaine, are metabolized by the liver, EXPAREL should be used cautiously in patients with hepatic disease.

### Warnings and Precautions Specific to EXPAREL

Avoid additional use of local anesthetics within 96 hours following administration of EXPAREL.

EXPAREL is not recommended for the following types or routes of administration: epidural, intrathecal, regional nerve blocks **other than interscalene brachial plexus nerve block**, or intravascular or intra-articular use.

The potential sensory and/or motor loss with EXPAREL is temporary and varies in degree and duration depending on the site of injection and dosage administered and may last for up to 5 days, as seen in clinical trials.

### Warnings and Precautions for Bupivacaine-Containing Products

**Central Nervous System (CNS) Reactions:** There have been reports of adverse neurologic reactions with the use of local anesthetics. These include persistent anesthesia and paresthesia. CNS reactions are characterized by excitation and/or depression.

**Cardiovascular System Reactions:** Toxic blood concentrations depress cardiac conductivity and excitability, which may lead to dysrhythmias, sometimes leading to death.

**Allergic Reactions:** Allergic-type reactions (eg, anaphylaxis and angioedema) are rare and may occur as a result of hypersensitivity to the local anesthetic or to other formulation ingredients.

**Chondrolysis:** There have been reports of chondrolysis (mostly in the shoulder joint) following intra-articular infusion of local anesthetics, which is an unapproved use.

**Methemoglobinemia:** Cases of methemoglobinemia have been reported with local anesthetic use.

Full Prescribing Information is available at [www.EXPAREL.com](http://www.EXPAREL.com).