

# Administration Case Report: Robotic Total Colectomy and End Ileostomy

This case report represents the individual experience of Dr Jeff Gadsden, and is intended to demonstrate his methodology for using EXPAREL in patients undergoing robotic total colectomy and end ileostomy.

Pacira BioSciences, Inc. recognizes that there are alternative methodologies for administering local anesthetics, as well as individual patient considerations when selecting the dose for a specific procedure.

EXPAREL is a local anesthetic that produces postsurgical analgesia in patients aged 6 years and older. It is administered via single-dose infiltration. When infiltrated into the surgical site, it produces local analgesia. It may also be infiltrated in the fascial plane to produce regional analgesia as a regional field block. Regional anesthetic techniques to produce regional analgesia include, but are not limited to, transversus abdominis plane (TAP) block, pectoralis (PEC) and serratus anterior plane (SAP) blocks, erector spinae plane (ESP) block, and quadratus lumborum (QL) block. EXPAREL may also be administered in adults as an interscalene brachial plexus nerve block, a sciatic nerve block in the popliteal fossa, and an adductor canal block to produce postsurgical regional analgesia.

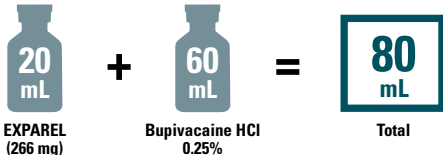
## CASE INFORMATION

<b>Physician Name</b>	Jeff Gadsden, MD, FRCPC, FANZCA
<b>Affiliation</b>	Associate Professor of Anesthesiology, Duke University School of Medicine, Durham, NC
<b>Surgical Case Performed</b>	Robotic total colectomy and end ileostomy
<b>Inpatient or Outpatient Procedure</b>	Inpatient

## PATIENT CHARACTERISTICS

<b>Gender</b>	Male
<b>Age</b>	37 years
<b>Patient History and Characteristics</b>	The patient has a 12-year history of medically refractory ulcerative colitis and presented for total colectomy with a staged reconstruction. Past history includes arthritis and anemia

## PROCEDURAL DETAILS

<b>Incision Size</b>	Multiple port placements widely spaced across the entire abdomen
<b>Dose of EXPAREL and Total Volume Used</b>	 <p>20 mL EXPAREL (266 mg) + 60 mL Bupivacaine HCl (0.25%) = 80 mL Total</p>

## MULTIMODAL ANALGESIA AND ENHANCED RECOVERY AFTER SURGERY PROTOCOL

<b>Intraoperative Medications Used</b>	80 mL of EXPAREL solution (40 mL for lateral TAP + 40 mL for subcostal TAP)
<b>Postoperative Medications Used</b>	Acetaminophen 975 mg PO q6h; celecoxib 200 mg PO q12h; ondansetron 4 mg q6h prn; oxycodone 5 to 10 mg PO q4h prn

PO=by mouth; prn=as needed; q4h=every 4 hours; q6h=every 6 hours; q12h=every 12 hours.

The recommended dose of EXPAREL for infiltration in adults is based on the size of the surgical site, the volume required to cover the area, and individual patient factors that may impact the safety of an amide local anesthetic. The maximum dose of EXPAREL should not exceed 266 mg. The recommended dose of EXPAREL for patients aged 6 to <17 years old is 4 mg/kg, up to a maximum of 266 mg. The recommended dose of EXPAREL in adults for interscalene brachial plexus nerve block, sciatic nerve block in the popliteal fossa, and adductor canal is 133 mg. The recommended dose of EXPAREL in adults for adductor canal block is 133 mg (10 mL) admixed with 50 mg (10 mL) of 0.5% bupivacaine HCl, for a total volume of 20 mL.

EXPAREL can be administered unexpanded (20 mL) or expanded to increase volume up to a total of 300 mL (final concentration of 0.89 mg/mL [ie, 1:14 dilution by volume]) with normal (0.9%) saline or lactated Ringer's solution.

Bupivacaine HCl (which is approved for use in patients aged 12 and older) may be administered immediately before EXPAREL or admixed in the same syringe, as long as the ratio of the milligram dose of bupivacaine HCl to EXPAREL does not exceed 1:2. Admixing may impact the pharmacokinetic and/or physicochemical properties of EXPAREL, and this effect is concentration dependent. The toxic effects of these drugs are additive and their administration should be used with caution, including monitoring for neurological and cardiovascular effects related to local anesthetic systemic toxicity. Other than with bupivacaine, EXPAREL should not be admixed with other drugs prior to administration.

**Please see Important Safety Information on the last page and refer to accompanying full Prescribing Information, which is also available at [www.EXPARELpro.com](http://www.EXPARELpro.com).**

## INFILTRATION NOTES

### ASSESSED THE SIZE OF THE SURGICAL SITE AND DEPTH OF TISSUE, THEN PREPARED INJECTION MATERIALS ACCORDINGLY

In this procedure, Dr Gadsden determined that a total volume of 80 mL would be needed to cover the surgical site. He admixed 20 mL of EXPAREL<sup>®</sup> (bupivacaine liposome injectable suspension) with 60 mL of bupivacaine HCl 0.25%. Bupivacaine HCl was added to provide early-onset analgesia and bridge the time to onset of the long-acting analgesia provided by EXPAREL.



In cases that require a higher total volume, such as those involving larger incisions, Dr Gadsden may add normal saline to increase the total volume to 100 mL.

### DIVIDED INJECTATE INTO SYRINGES WITH NEEDLE SIZES APPROPRIATE FOR INFILTRATION (20- TO 25-GAUGE) AND PLANNED WHICH AREAS TO INFILTRATE WITH EACH INJECTION

For this procedure, Dr Gadsden divided the injectate into 4 syringes with 21-gauge needles, each containing 5 mL (66.5 mg) of EXPAREL and 15 mL (37.5 mg) 0.25% bupivacaine HCl.

Four-point TAP block was performed at the conclusion of the surgical procedure, after the surgical drapes were removed and before the patient emerged from anesthesia.



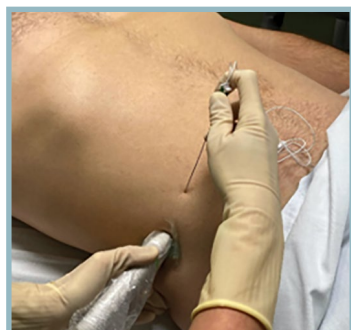
In obese patients, identification of the precise plane can be challenging because of the appearance of multiple “layers” to the abdominal wall. Toggling the probe back and forth in a cephalocaudal direction will cause the oblique muscles to appear as if moving in opposite directions, whereas the fat and transversus abdominis muscle remain static. This allows the operator to quickly recognize the internal oblique muscle.

### ■ Step #1: Bilateral lateral (“classic”) TAP block

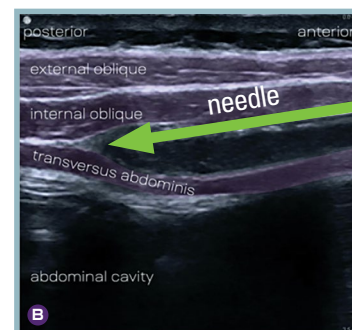
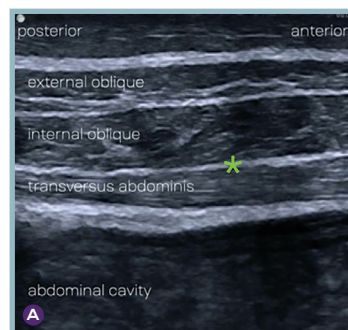A linear ultrasound probe was placed in a transverse orientation on the midaxillary line at the level of the umbilicus (approximately equidistant from the iliac crest and costal margin) (Figure 1). The transversus abdominis plane was then identified as a bright hyperechoic line between the internal oblique and transversus abdominis muscles (Figure 2A). A 21-gauge, 100-mm needle was advanced from the anterior aspect of the probe until the tip was observed entering the transversus abdominis plane. Small boluses (1 mL) of saline were injected to confirm needle position between the 2 muscles, and the needle was redirected to ensure the tip was not intramuscular. Once satisfied with the needle position, Dr Gadsden slowly infiltrated 20 mL of the EXPAREL mixture. The correct injection plane was confirmed by observing the 2 muscles “unzipping” (Figure 2B). The needle was advanced posteriorly in the plane as needed to continue to dissect the muscles. The block was then repeated on the contralateral side.

**FIGURE 1.** Ultrasound transducer orientation and needle insertion for lateral (“classic”) TAP block

#### Lateral TAP



**FIGURE 2.** Sonoanatomy showing abdominal wall muscles, the injection plane (\*), and the needle direction for the lateral TAP block. The pool of EXPAREL mixture is seen in the correct plane



**INFILTRATION NOTES (cont)**



Despite our best efforts, occasionally the TAP plane fails to unzipper (“hydrodissect”) easily. In these cases, placing the EXPAREL<sup>®</sup> (bupivacaine liposome injectable suspension) mixture deep to the fascial plane (ie, on the surface of transversus abdominis muscle) provides the “next best” location for the injectate, as the nerves travel on the surface of this muscle, not superficial to the TAP plane.

**■ Step #2: Bilateral subcostal TAP block**

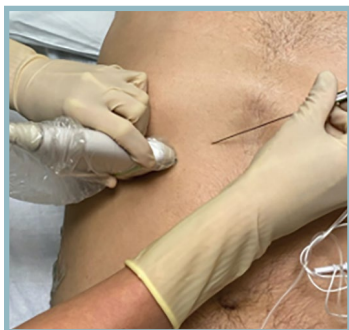A linear ultrasound probe was placed on the epigastrium parallel to the costal margin, 3 to 4 cm lateral to the midline (Figure 3). The lateral edge of rectus abdominis muscle was visualized on the screen, and the transversus abdominis muscle deep to it (Figure 4A). A 21-gauge, 100-mm needle was advanced from the medial aspect of the probe until the tip was observed entering the fascial plane between the rectus and transversus muscles. Small boluses (1 mL) of saline were injected to confirm needle position between the 2 muscles, and the needle redirected to ensure the tip was not intramuscular. Once satisfied with the needle position, Dr Gadsden slowly infiltrated 20 mL of the EXPAREL mixture. The correct injection plane was confirmed by observing the 2 muscles unzipping (Figure 4B). The needle was continuously advanced inferolaterally in the transversus abdominis plane as the rectus muscle disappeared from view and the internal oblique muscle appeared. Once it had traveled as far as possible between the internal oblique and transversus muscles, the needle was withdrawn and the block repeated on the contralateral side.



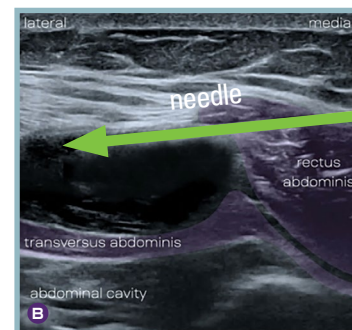
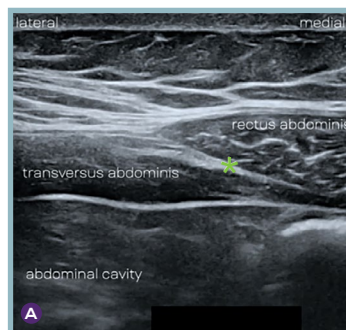
The more parallel the needle path with respect to the TAP plane, the easier the hydrodissection and needle advancement within the plane itself. Calculate the distance between the skin and the TAP plane, and insert the needle away from the probe by that distance (Figure 1). The needle should be advanced upward toward the probe surface initially, to avoid the abdominal cavity, then redirected as needed to enter the TAP plane.

**FIGURE 3.** Ultrasound transducer orientation and needle insertion for subcostal TAP block

**Subcostal TAP**



**FIGURE 4.** Sonoanatomy showing abdominal wall muscles, the injection plane (\*), and the needle direction for the subcostal TAP block. The pool of EXPAREL mixture is seen in the correct plane



Dr Gadsden always uses normal saline to hydrolocate the needle tip and ensure that the expanded EXPAREL mixture will be deposited in the correct fascial plane, minimizing wastage of EXPAREL within the muscle itself.



Watch Dr Gadsden infiltrate with EXPAREL in a robotic total colectomy and end ileostomy procedure at [www.EXPARELpro.com](http://www.EXPARELpro.com)

## IMPORTANT SAFETY INFORMATION

### Indication

EXPAREL<sup>®</sup> (bupivacaine liposome injectable suspension) is indicated to produce postsurgical local analgesia via infiltration in patients aged 6 years and older and regional analgesia in adults via an interscalene brachial plexus nerve block, sciatic nerve block in the popliteal fossa, and an adductor canal block. Safety and efficacy have not been established in other nerve blocks.

### Important Safety Information

EXPAREL is contraindicated in obstetrical paracervical block anesthesia.

Adverse reactions reported in adults with an incidence greater than or equal to 10% following EXPAREL administration via infiltration were nausea, constipation, and vomiting; adverse reactions reported in adults with an incidence greater than or equal to 10% following EXPAREL administration via nerve block were nausea, pyrexia, headache, and constipation.

Adverse reactions with an incidence greater than or equal to 10% following EXPAREL administration via infiltration in pediatric patients six to less than 17 years of age were nausea, vomiting, constipation, hypotension, anemia, muscle twitching, vision blurred, pruritus, and tachycardia.

Do not admix lidocaine or other non-bupivacaine local anesthetics with EXPAREL. EXPAREL may be administered at least 20 minutes or more following local administration of lidocaine.

EXPAREL is not recommended to be used in the following patient populations: patients <6 years old for infiltration, patients younger than 18 years old for nerve blocks, and/or pregnant patients.

Because amide-type local anesthetics, such as bupivacaine, are metabolized by the liver, EXPAREL should be used cautiously in patients with hepatic disease.

### Warnings and Precautions Specific to EXPAREL

Avoid additional use of local anesthetics within 96 hours following administration of EXPAREL.

EXPAREL is not recommended for the following types or routes of administration: epidural, intrathecal, regional nerve blocks **other than interscalene brachial plexus nerve block, sciatic nerve block in the popliteal fossa, and adductor canal block**, or intravascular or intra-articular use.

The potential sensory and/or motor loss with EXPAREL is temporary and varies in degree and duration depending on the site of injection and dosage administered and may last for up to 5 days, as seen in clinical trials.

### Warnings and Precautions for Bupivacaine-Containing Products

**Central Nervous System (CNS) Reactions:** There have been reports of adverse neurologic reactions with the use of local anesthetics. These include persistent anesthesia and paresthesia. CNS reactions are characterized by excitation and/or depression.

**Cardiovascular System Reactions:** Toxic blood concentrations depress cardiac conductivity and excitability, which may lead to dysrhythmias, sometimes leading to death.

**Allergic Reactions:** Allergic-type reactions (eg, anaphylaxis and angioedema) are rare and may occur as a result of hypersensitivity to the local anesthetic or to other formulation ingredients.

**Chondrolysis:** There have been reports of chondrolysis (mostly in the shoulder joint) following intra-articular infusion of local anesthetics, which is an unapproved use.

**Methemoglobinemia:** Cases of methemoglobinemia have been reported with local anesthetic use.

**Disclosure:** Dr Gadsden is a paid consultant for Pacira BioSciences, Inc.

**Full Prescribing Information is available at [www.EXPARELpro.com](http://www.EXPARELpro.com).  
For more information, please visit [www.EXPARELpro.com](http://www.EXPARELpro.com) or call 1-855-793-9727.**